SECONDARY GLAUCOMAS

1. Pseudoexfoliation glaucoma
2. Pigmentary glaucoma
3. Neovascular glaucoma
4. Inflammatory glaucomas
5. Phacolytic glaucoma
6. Post-traumatic angle recession glaucoma
7. Iridocorneal endothelial syndrome
8. Glaucoma associated with iridoschisis

Pseudoexfoliation glaucoma

- Secondary trabecular block open-angle glaucoma
- Affects elderly, unilateral in 60%
- Prognosis less good than in POAG

Pseudoexfoliative material	Iris sphincter atrophy	Gonioscopy
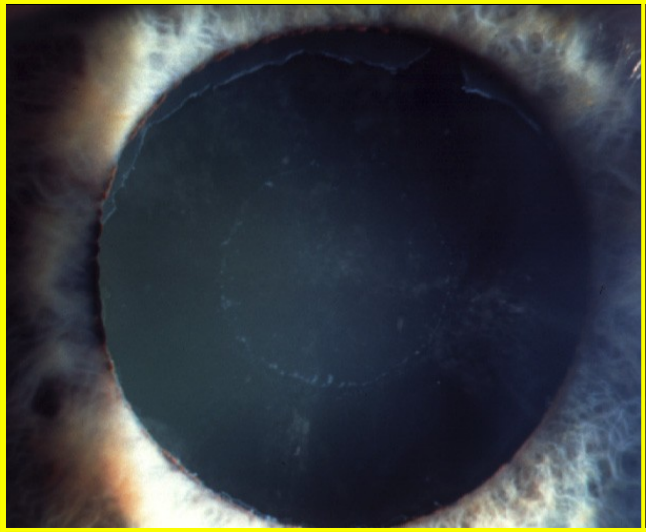	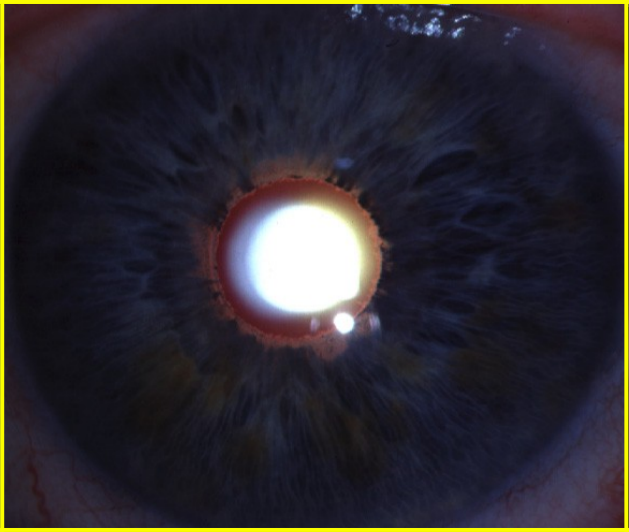	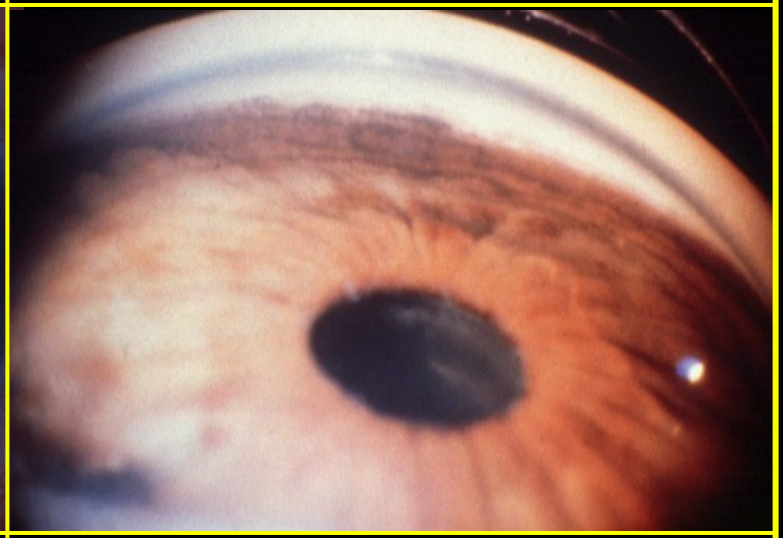
Central disc with peripheral band	On retroillumination	Trabecular hyperpigmentation - may extend anteriorly (Sampaolesi line)

Pigmentary glaucoma

- Bilateral trabecular block open-angle glaucoma
- Typically affects young myopic males
- Increased incidence of lattice degeneration

Krukenberg spindle and very deep anterior chamber

Fine pigment granules on anterior iris surface

Mid-peripheral iris atrophy

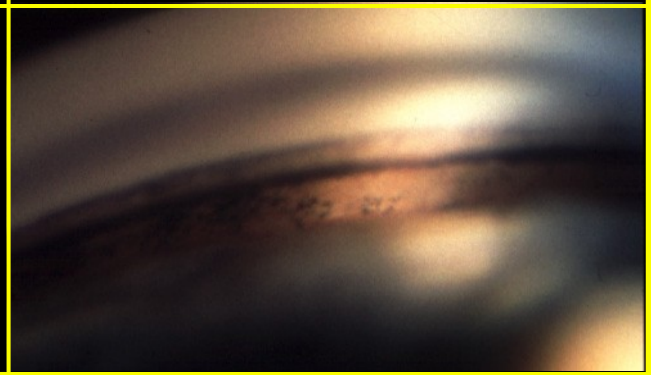

Trabecular hyperpigmentation

Causes of neovascular glaucoma

- Common, secondary angle-closure glaucoma without pupil block
- Caused by rubeosis iridis associated with chronic, diffuse retinal ischaemia

Ischaemic central retinal vein occlusion (most common)

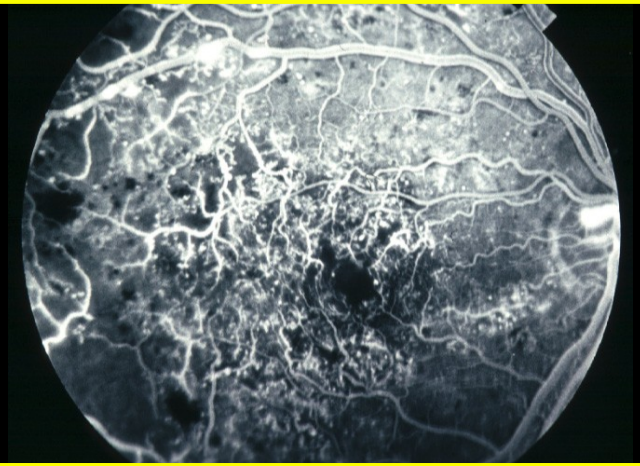

Long-standing diabetes (common)

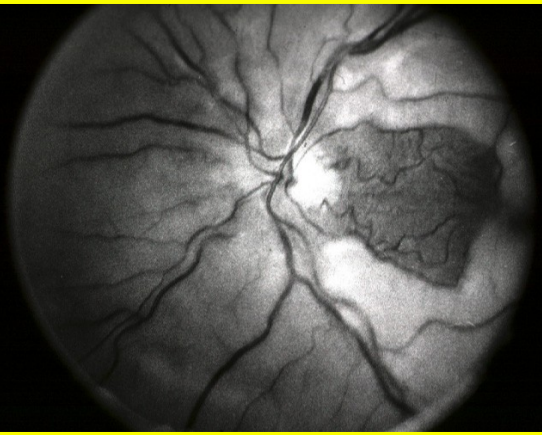

Central retinal artery occlusion (uncommon)

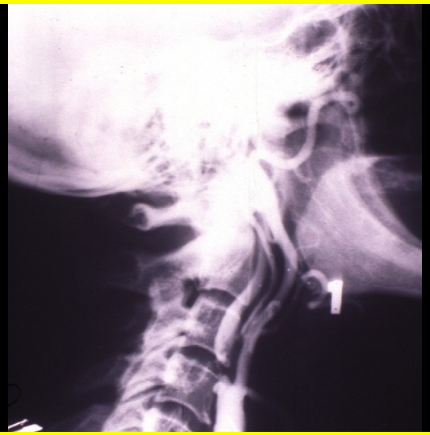

Carotid obstructive disease (uncommon)

Signs of advanced neovascular glaucoma

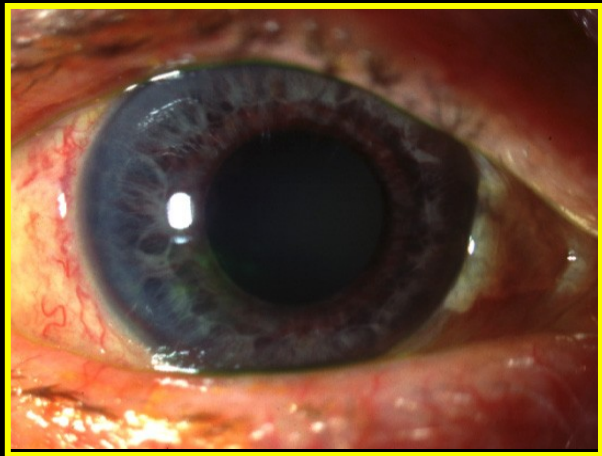

Severely reduced visual acuity, congestion and pain

Severe rubeosis iridis

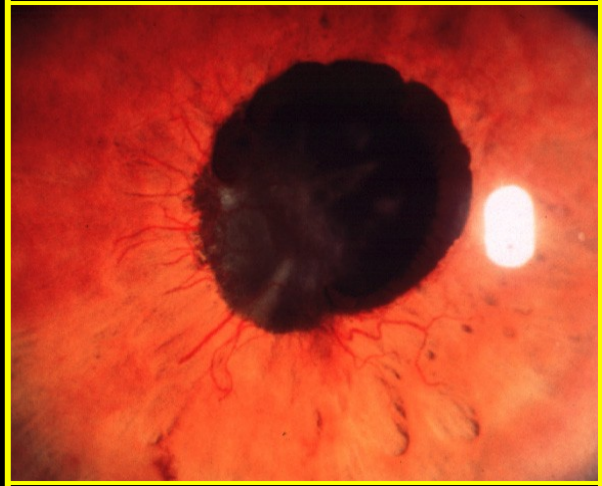

Distortion of pupil and ectropion uveae

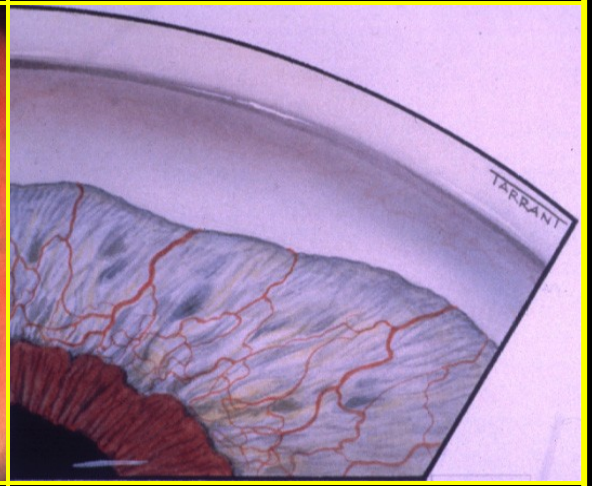

Synechial angle closure

Treatment options of neovascular glaucoma

Topical

- Atropine and steroids to decrease inflammation
- Beta-bockers

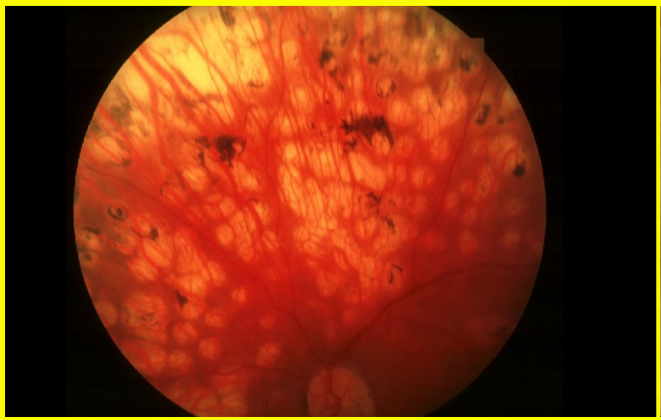

Panretinal photocoagulation
- in early cases

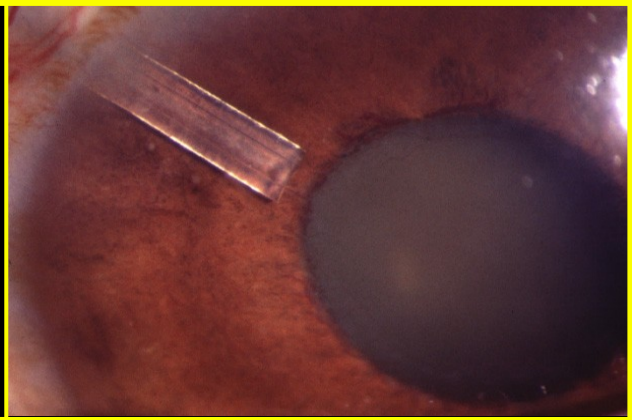

Artificial filtering devices
- in very advanced cases

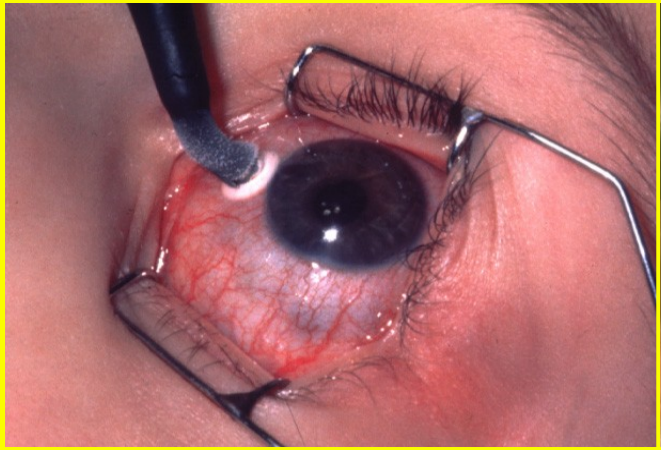

Cyclodestructive procedures
- to relieve pain

Retrobulbar alcohol injection
- to relieve pain

Inflammatory glaucomas

Angle-closure with pupil block

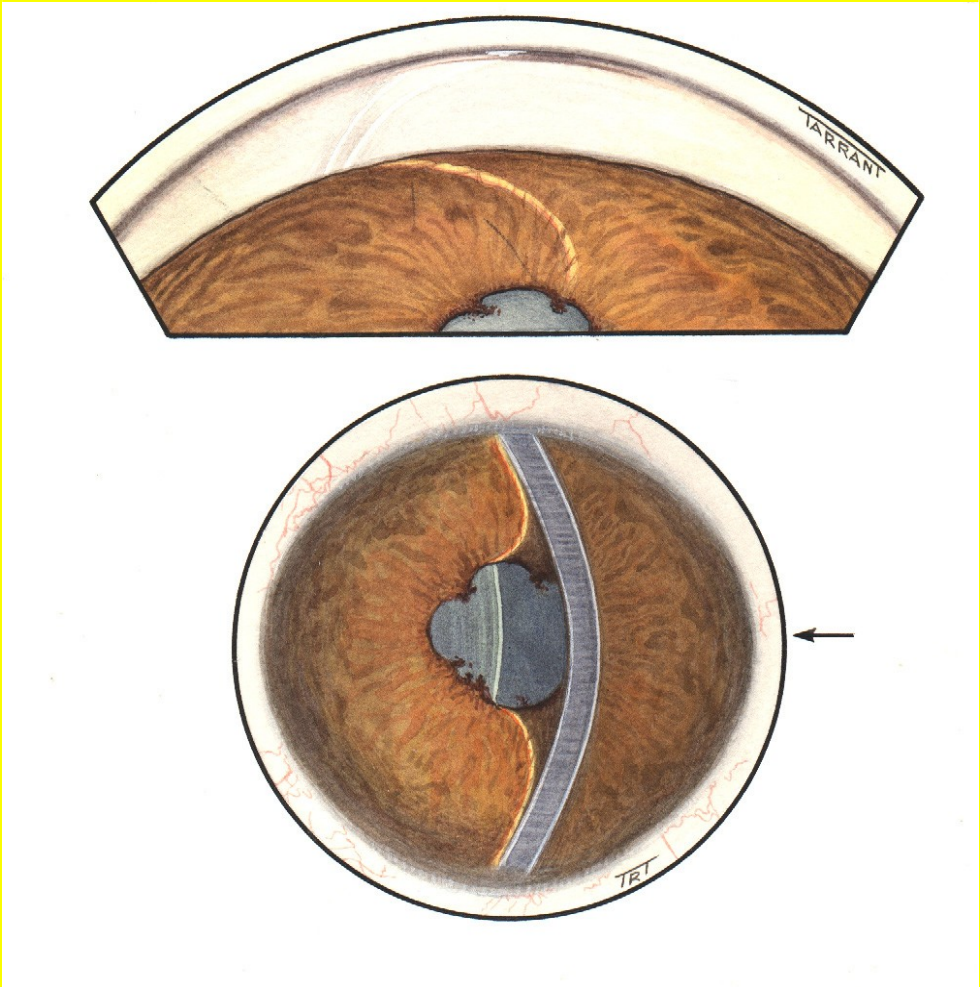

- Caused by seclusio pupillae
- Anterior chamber is shallow

Inflammatory glaucomas

Angle-closure without pupil block

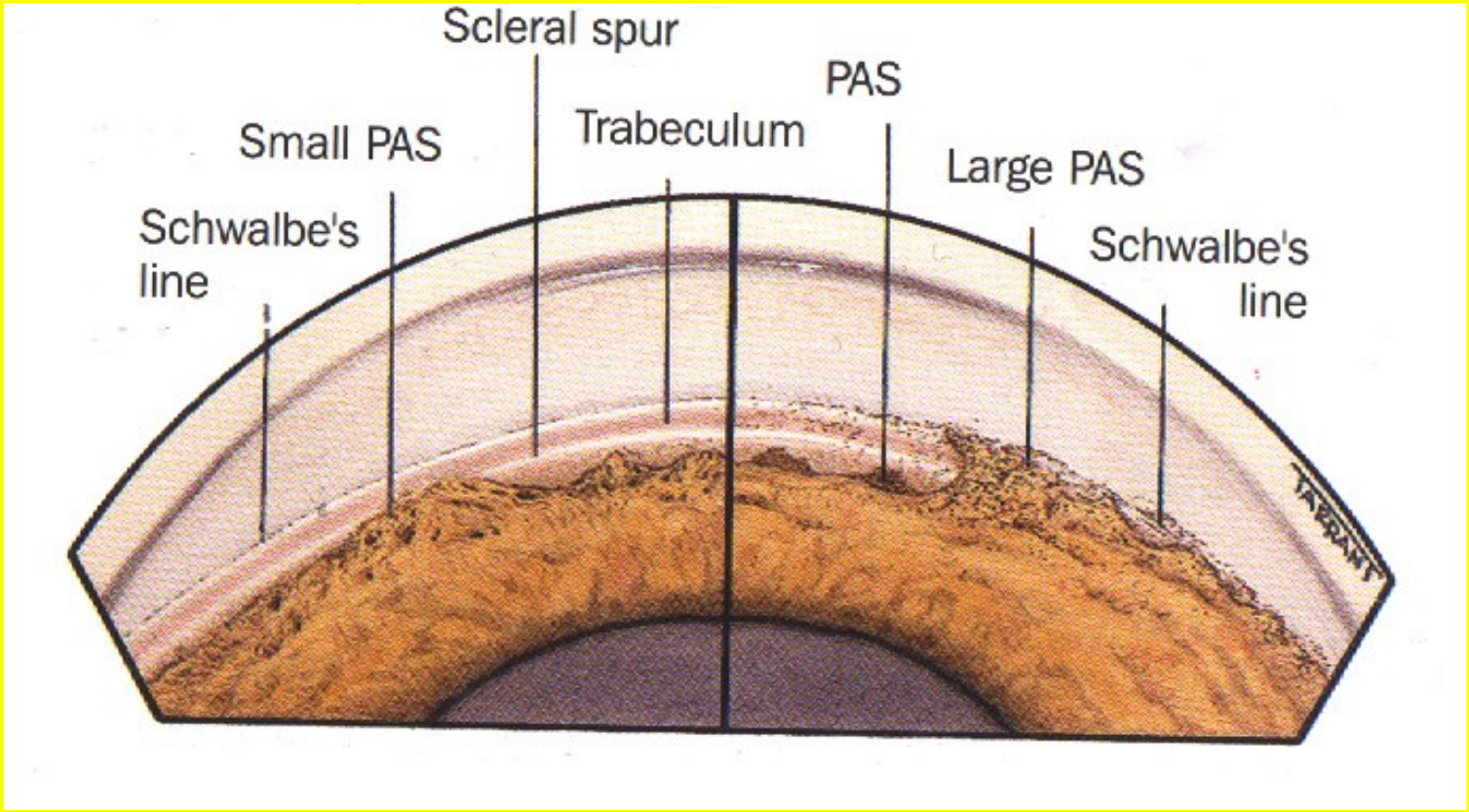

- Caused by progressive synechial angle closure
- Anterior chamber is deep

Phacolytic glaucoma

Pathogenesis

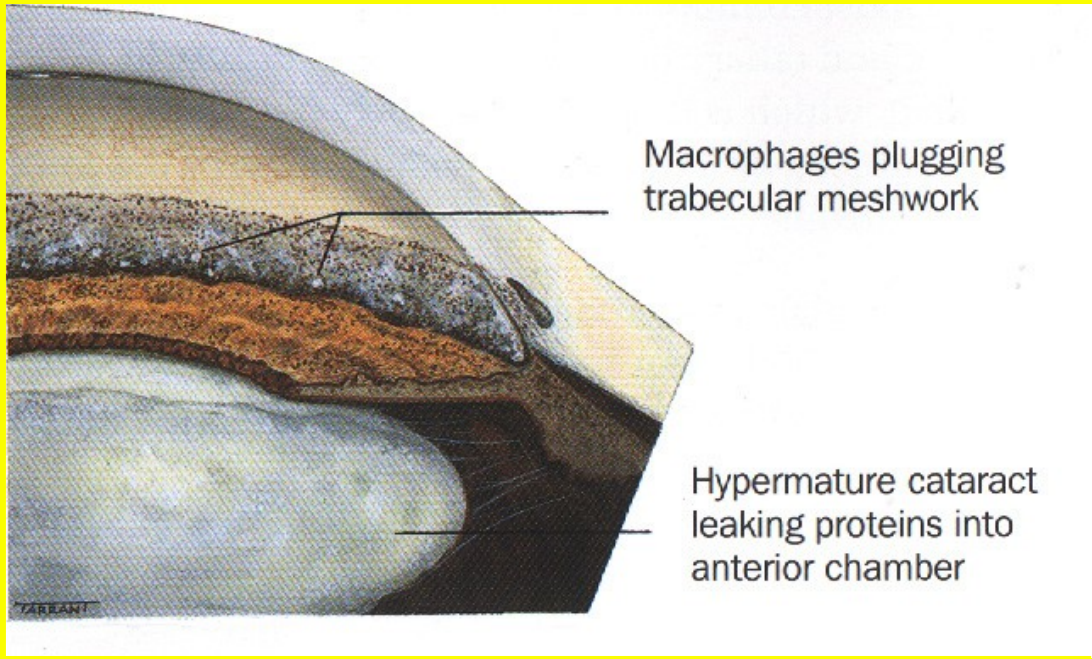

Signs

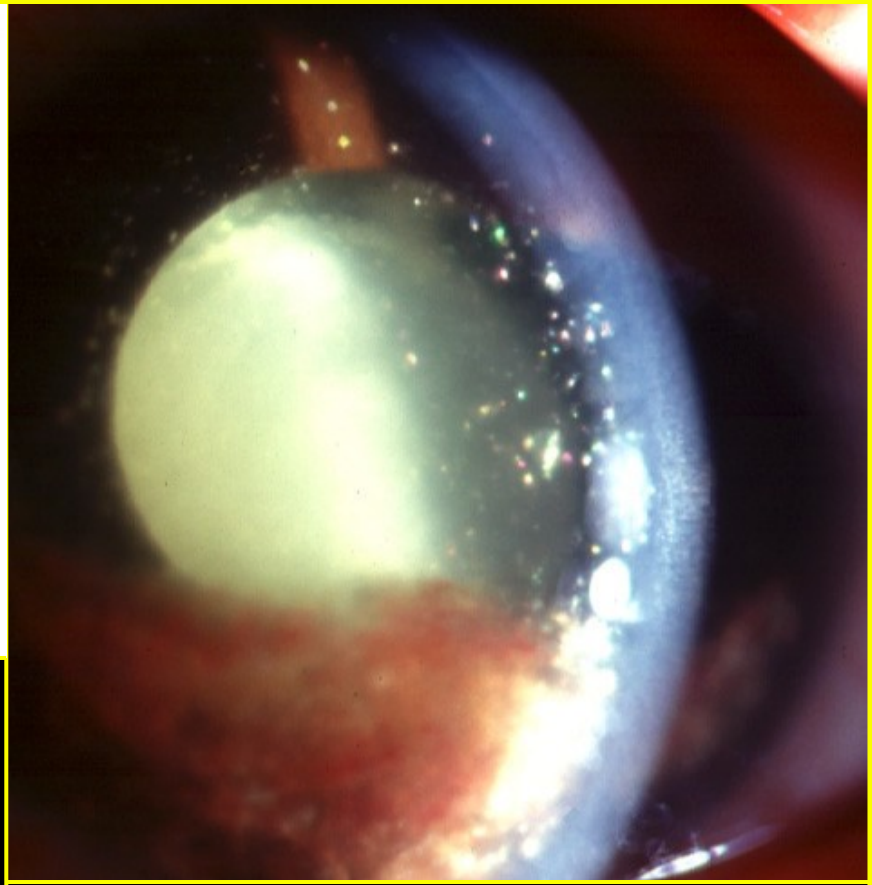

- Deep anterior chamber
- Floating white particles

Treatment

- Control IOP medically
- Remove cataract

Post-traumatic angle recession glaucoma

Pathogenesis	Signs
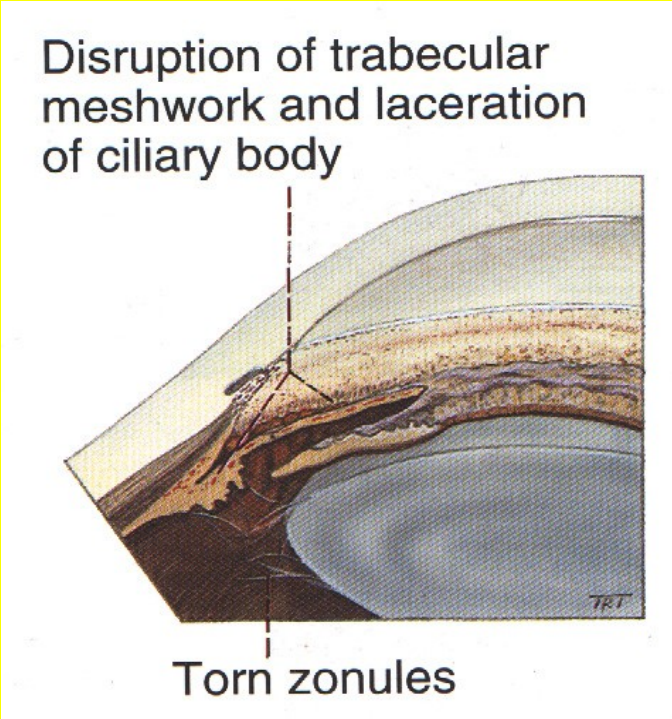	
Blunt traumatic damage to trabecular meshwork	**Irregular widening of ciliary body band**

Classification of Iridocorneal Endothelial Syndrome

- Proliferation of abnormal corneal endothelial cells
- Typically affects young to middle aged women
- Three syndromes with certain overlap

1. **Progressive iris atrophy**
   - Iris atrophy in 100%
2. **Iris naevus (Cogan-Reese) syndrome**
   - Iris atrophy in 50%
3. **Chandler syndrome**
   - Iris atrophy in 40%
   - Corneal changes predominate

Progressive iris atrophy

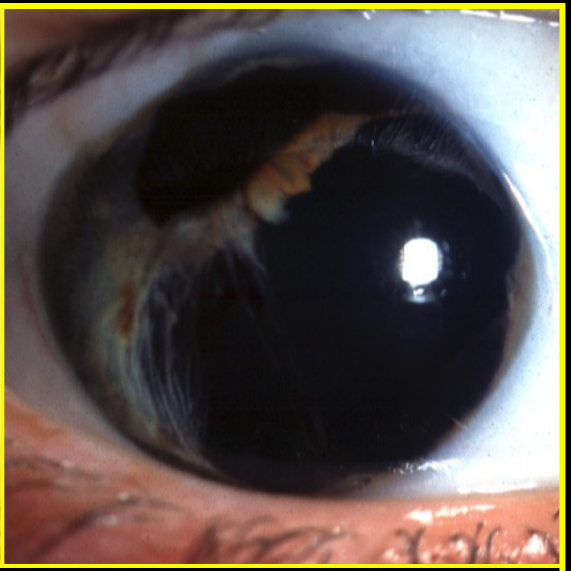

Progressive stromal iris atrophy



Broad-based PAS

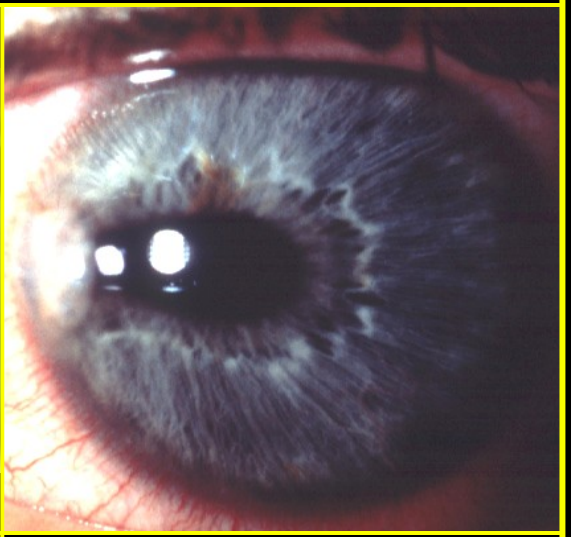

Displacement of pupil towards PAS

Iris naevus (Cogan-Reese) syndrome

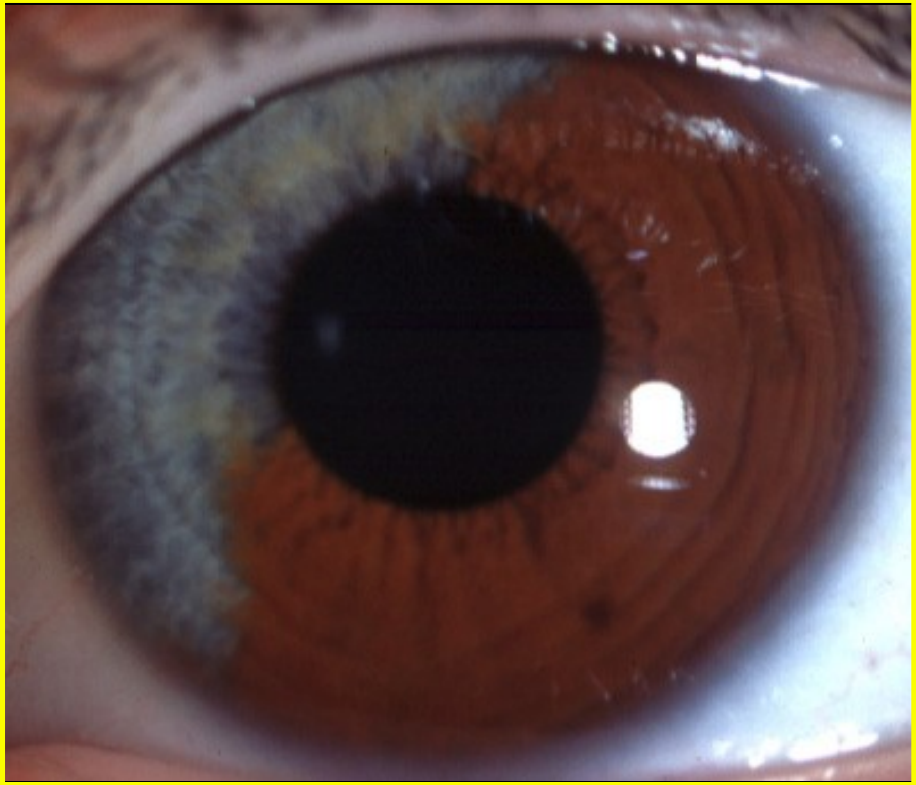

Diffuse iris naevus

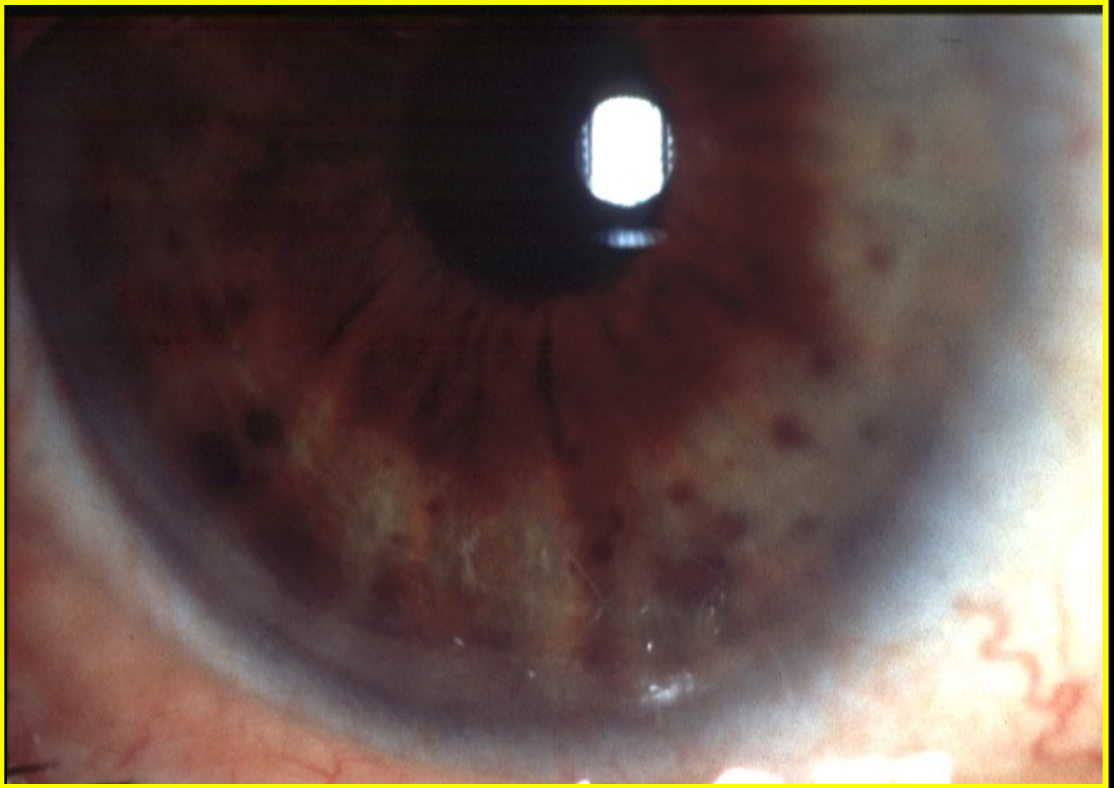

Pedunculated iris nodules

Chandler syndrome

Initially ‘hammer-silver’ endothelial changes

Later oedema which may cause halos

Glaucoma associated with iridoschisis

- Rare, affects elderly, often bilateral
- Underlying, angle-closure glaucoma in about 90%

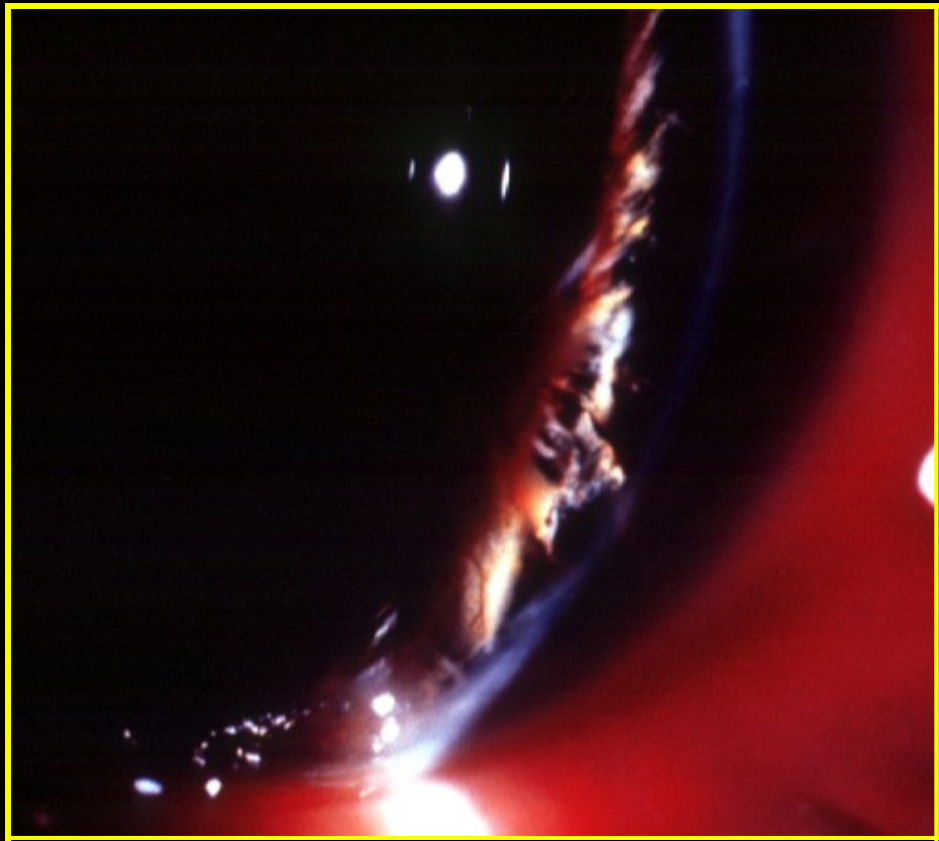

Shallow anterior chamber

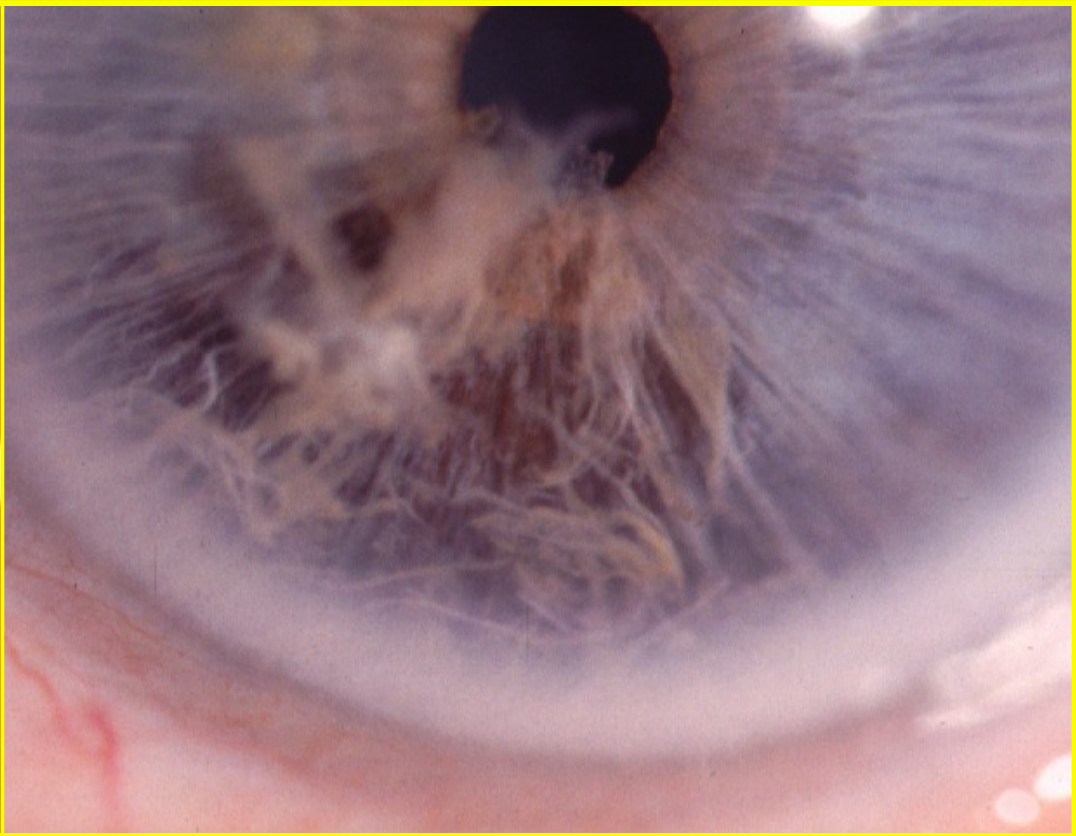

Iridoschisis - usually inferior